

See discussions, stats, and author profiles for this publication at: <https://www.researchgate.net/publication/323124247>

Morphological and morphometric analysis of accessory mental foramen in dry human mandibles of south indian population

Article in *Indian Journal of Dental Research* · January 2018

DOI: 10.4103/ijdr.IJDR_146_17

CITATIONS

12

READS

197

4 authors, including:



Priyanka Daniel

St George's, University of London

21 PUBLICATIONS 94 CITATIONS

[SEE PROFILE](#)



Suganthy Rabi

Christian Medical College & Hospital

88 PUBLICATIONS 927 CITATIONS

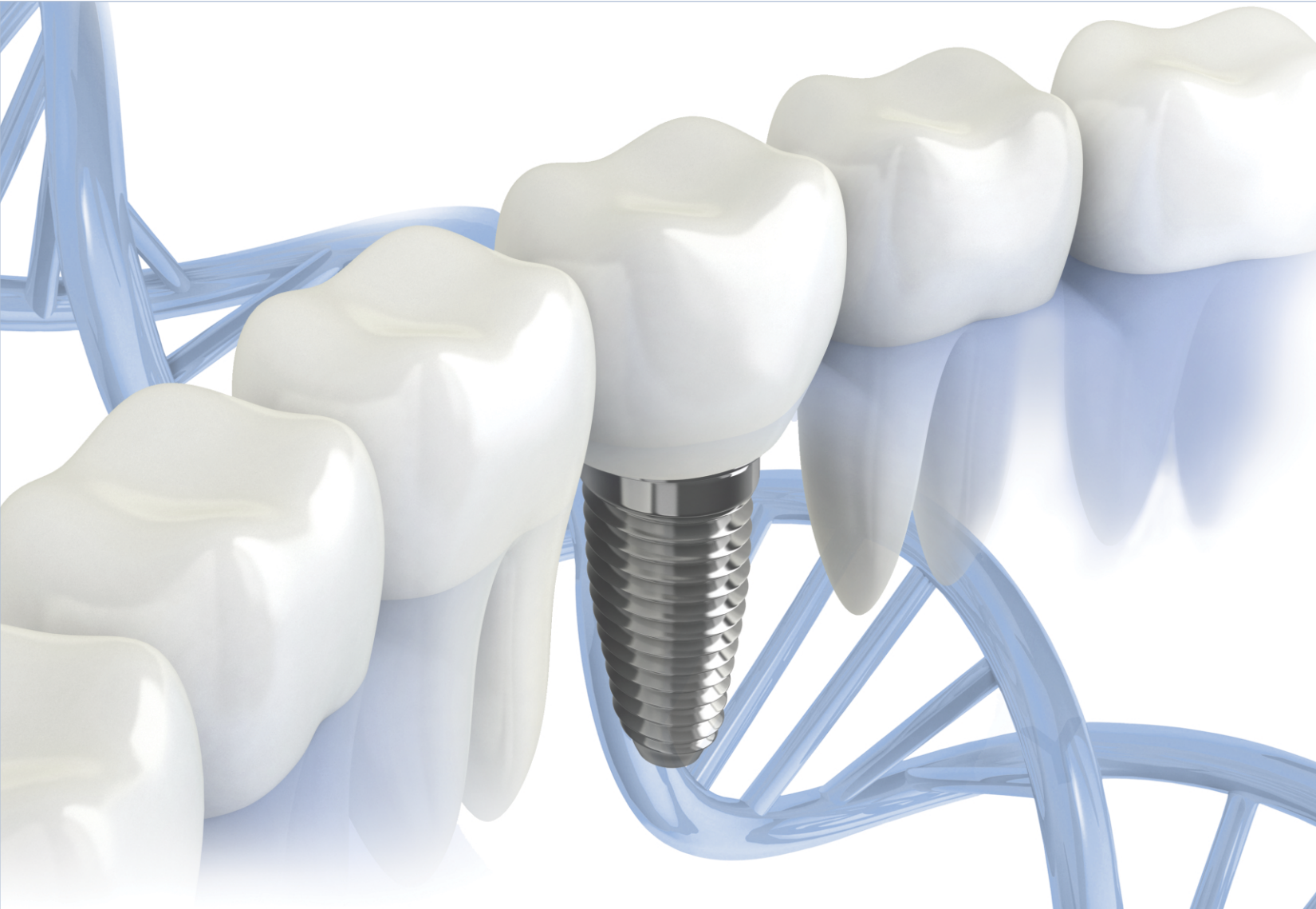
[SEE PROFILE](#)



IJDR

Indian Journal of Dental Research

www.ijdr.in



Official Publication of

Indian Society for Dental Research

www.isdrindia.com

International Association for Dental Research - Indian Division

www.iadr.com

Morphological and Morphometric Analysis of Accessory Mental Foramen in Dry Human Mandibles of South Indian Population

Abstract

Background: Mental foramen (MF) is an important landmark for administration of local anesthesia in surgical procedures involving the mandible. Additional mental foramina, called accessory mental foramina (AMF) transmitting branches of mental nerve, have been reported. Detection of AMFs in presurgical imaging may reduce postoperative pain in dental surgical procedures. **Aim:** The aim of the study was to study the incidence and morphometric analysis of accessory MF in the dry human mandibles of South Indian population. **Materials and Methods:** Two hundred and sixty dry human mandibles were studied for the presence, location, shape of AMF, and its relation to MF. The horizontal diameter of AMF, and its distance from symphysis menti, the posterior border of mandible and from the base of mandible were measured and statistically analyzed. **Results and Conclusions:** In our study, AMF were present in 8.85% mandibles (unilateral - 7.6% [4.6% - left, 2.69% - right] and bilateral 1.6%). The most common position was below the second premolar (48.1%). AMF were round in shape (74%) and was often located either superomedial or inferolateral to MF. Their transverse diameter ranged from 0.5 to 1 mm. The AMF were situated at a mean distance of 2.96 mm from MF, 23.47 mm from symphysis menti, 11.24 mm from the lower border of the body of the mandible, and 57.35 mm from the posterior border of ramus of mandible. The knowledge of the presence of AMF and its dimensions would enable the clinicians to do mandibular procedures carefully and avoid injury to the branches of mental nerve that may be passing through it.

Keywords: Accessory mental foramen, accessory mental nerve, dental implant, mental foramen, mental nerve

Introduction

The mental foramen (MF) is a bilateral small opening located on the anterolateral aspect of the mandible and transmits the mental nerve, a branch of the inferior alveolar nerve, the corresponding artery, and vein. The direction of opening of the MF is outward and upward in a posterior direction.^[1] The MF is usually present between the premolars.^[2] It is an important anatomical landmark in the mandible for mental nerve identification, administration of local anesthesia, and various surgical procedures on the mandible in the field of dentistry.^[3] Anatomical variations in the position of MF are very rare but variations in the number of mental foramina have been reported with more than one MF present on one or both sides of mandible. These additional foramina located in the vicinity of MF are termed as accessory mental foramina (AMF).^[4] AMF are reported to be a rare anatomical variation

and has been found to transmit myelinated nerves, one or more arterioles and venules. The accessory mental nerve traversing the AMF is considered to be a branch of the inferior alveolar nerve and is distributed to the mucous membranes, the skin of the corner of the mouth, and the median labial region.^[5] Although AMF have been reported earlier, literature regarding its incidence and topography is sparse. The purpose of the present study is to analyze the incidence and topography of AMF in dry human mandibles of South Indian population.

Materials and Methods

Approval from the Institutional Review Board was obtained. The dry human mandibles used for the present study were procured from the Department of Anatomy of our institution. The required sample size to find the incidence of AMF was found to be 204 mandibles with 3.5% precision and 95% confidence limits. A total of 260 (520 sides) dry adult human mandibles of South

**Rajkohila J,
Priyanka Daniel,
Sakunthala
Ambikaipakan¹,
Suganthi Rabi**

*Department of Anatomy,
Christian Medical College,
Vellore, Tamil Nadu, India,
¹Department of Anatomy,
University of Jaffna, Jaffna,
Sri Lanka*

Address for correspondence:

*Dr. Priyanka Daniel,
Department of Anatomy,
Christian Medical College,
Vellore, Tamil Nadu, India.
E-mail: priyanka.daniel@
gmail.com*

Access this article online

Website: www.ijdr.in

DOI: 10.4103/ijdr.IJDR_146_17

Quick Response Code:



How to cite this article: Rajkohila J, Daniel P, Ambikaipakan S, Rabi S. Morphological and morphometric analysis of accessory mental foramen in dry human mandibles of south indian population. Indian J Dent Res 2018;29:56-60.

This is an open access article distributed under the terms of the Creative Commons Attribution-NonCommercial-ShareAlike 3.0 License, which allows others to remix, tweak, and build upon the work non-commercially, as long as the author is credited and the new creations are licensed under the identical terms.

For reprints contact: reprints@medknow.com

Indian origin, irrespective of age and sex, with either all teeth intact or with preserved alveolar margins were included in this study. The bones with gross pathological deformities were excluded from the study. The presence, location, shape of AMF, and its relation to MF were studied using visual examination. The topographical anatomy of AMF with respect to the borders was also measured with the help of a digital vernier caliper at a measuring accuracy of 0.001 mm. The horizontal diameter of AMF was also measured. In addition, various parameters, namely, the distance of AMF from the symphysis menti, the posterior border of the mandible and from the base of the mandible were also measured and statistically analyzed [Figure 1]. Frequencies and percentages were calculated for categorical data and mean along with standard deviation was calculated for continuous data.

Results

Of the 260 (520 sides) dry human mandibles studied, AMF were present in 23 mandibles (8.85%). Unilateral AMF were noted in 19 cases (7.3%) (12 - left side [4.6%] and 7 - right side [2.69%]) and bilateral in 4 cases (1.6%) [Figure 2], thus 27 AMF were observed in 260 mandibles. In our study, AMF in each mandible showed a variable location, namely, below first premolar (14.8%), between premolars (11.1%), below second premolar (48.1%), between second premolar and first molar (14.8%), below first molar (3.7%), and between first and second molar (7.4%) [Table 1 and Figure 3]. The most common position of AMF was below the second premolar on the anterolateral surface of the mandible. The AMF were round in shape in most of the mandibles (74%) and elliptical in the rest. Most of the AMF were located either superomedial or inferolateral (25.9%) in relation to MF [Table 2].

In 59.3% (16 AMF), the transverse diameter ranged from 0.5 to 1 mm [Table 3]. The AMF were situated at an average distance of 2.96 mm from the MF and at an

average distance of 23.47 from symphysis menti. The mean distance of AMF from the lower border of the body of the mandible was 11.24 mm. The AMF were positioned at an average distance of 57.35 from the posterior border of ramus of mandible [Table 4].

Table 1: Position of accessory mental foramen (n=27)

Position of AMF	n (%)
Below first premolar	4 (14.8)
Between first and second premolar	3 (11.1)
Below second premolar	13 (48.1)
Between second premolar and first molar	4 (14.8)
Below first molar	1 (3.7)
Between first and second molar	2 (7.4)

AMF=Accessory mental foramen

Table 2: Relation of accessory mental foramen to mental foramen (n=27)

Relation of AMF to mental foramen	n (%)
Superior	3 (11.1)
Superomedial	7 (25.9)
Superolateral	3 (11.1)
Medial	4 (14.8)
Inferior	0
Inferolateral	7 (25.9)
Lateral	3 (11.1)

AMF=Accessory mental foramen

Table 3: Transverse diameter of accessory mental foramen (n=27)

Diameter of AMF (mm)	n (%)
<0.5	1 (3.7)
0.5-1	16 (59.3)
1-2	5 (18.5)
2-3	3 (11.1)
>3	2 (7.4)

AMF=Accessory mental foramen

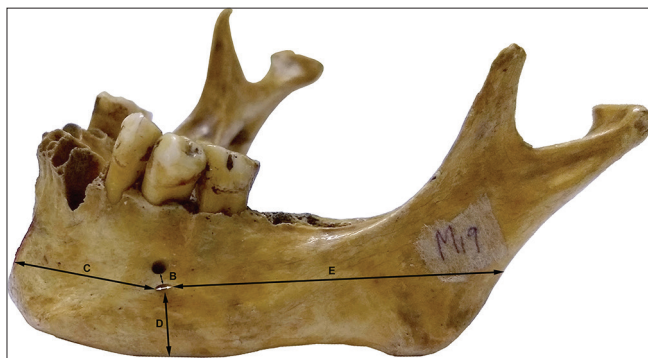


Figure 1: Picture to show the points of measurements and the distances measured. White arrow = Transverse diameter of AMF, B = distance between MF and AMF, C = distance of AMF from symphysis menti, D = distance of AMF from lower border of the body of mandible, E = distance of AMF from the posterior border of ramus of mandible. AMF = accessory mental foramina

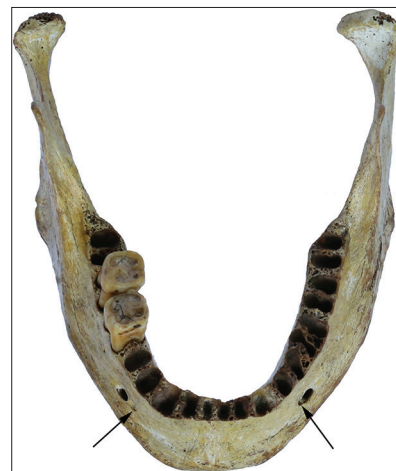

Figure 2: Thin black arrows showing the presence of bilateral accessory mental foramina

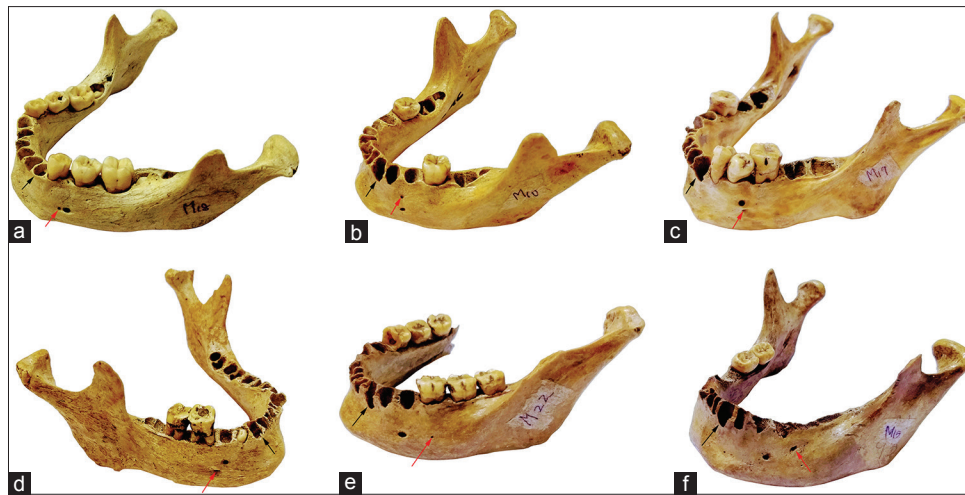

Figure 3: Picture to show the various positions of AMF based on their location (black arrow indicates the canine fossa for reference and red arrow indicates the AMF). (a) AMF below first premolar, (b) AMF between first and second premolar, (c) AMF below second premolar, (d) AMF between second premolar and first molar, (e) AMF below first molar, (f) AMF between first and second molar. AMF = Accessory mental foramina

Table 4: Distance of accessory mental foramen from various bony landmarks

Measurements	Mean±SD	Minimum	Maximum
From mental foramen	2.96±2.07	0.5	8.4
From symphysis menti	23.47±6.53	2.62	35.77
From lower border of body of mandible	11.24±2.62	6.07	18.27
From posterior border of ramus of mandible	57.35±5.98	45.4	68

SD=Standard deviation

Discussion

The MF provides a passage for exit of the mental nerve and vessels.^[6,7] MF is frequently single in human beings; more than one is termed accessory MF. If present, AMF transmit either the accessory mental nerve, which itself is a branch of inferior alveolar nerve, or one of the branches of mental nerve. These AMF are usually smaller in comparison to the MF and are located on the perimandibular surface surrounding the area of the MF.^[8] Failure to identify and protect AMF and structures traversing it might be the reason for failure to achieve an adequate level of mental nerve anesthesia. It may also result in accidental damage to the accessory nerves with neurosensory disturbances or rarely traumatic neuroma.^[9,10]

AMF are a rare anatomical variation and reported to have a prevalence ranging from 1.4% to 10%.^[11] The presence of AMF has been reported by investigations on dry human skull, cadaveric dissections, and radiological studies.^[3] The incidence of AMF has been found to be variable in different populations (1.5% in Russians, 2.6% in French, 2.8% in Israeli population, 3% in Hungarians, 3.3% in Greeks, 3.6% in Egyptians, 4% in American Whites, 5.7% in American Blacks, 9.7% in Melanesians, and 12.5% in Polynesians) with highest incidence in Negros and Maori

males.^[3,6,12,13] In the present study, the incidence in South Indian population was found to be 8.85%.

In the present study, AMF were located more on the left side than on the right side. This is in accordance with previous studies where Singh and Srivastav found 8% AMFs on the left side and 5% on the right side; Udhaya *et al.* found 3.33% AMFs on the left side and 2.22% on right side.^[6,14] Voljevica *et al.* reported the presence of four AMF, all of which were situated on the right side of the mandible.^[15] Previous studies have shown that bilateral AMF is an extremely rare finding and has been reported only in 0.53% of total population.^[16] Contrary to that, bilateral occurrence of AMF has been reported in 2% of South Indian population.^[17] The present study revealed 1.6% bilateral AMF, indicating that bilateral AMF occurrence is more in Indian population.

The site and size of the AMF are thought to be influenced by the nerve passing through it. Hu *et al.* described four terminal branches of the mental nerve as angular, medial inferior labial, lateral inferior labial, and mental branches.^[18] The nerve emerging from AMF has been described as either being one of the terminal branches of mental nerve given off in the mandibular canal or the presence of an additional branch, called accessory mental nerve which is considered to be a branch of the inferior alveolar nerve which might have separated earlier than formation of mental foramina.^[5,19,20] This accessory mental nerve is thought to innervate mucus membranes, skin of the corner of the mouth, and the median labial region.^[21]

Hauser and De Stefano stated that different variants occur due to epigenetic traits which further undergo modifications during ontogeny and variable degrees of expression; hence, the variations encountered in AMF regarding its number, size, position, and shape depend on gene modification.^[22]

The MF is usually directed posterosuperiorly and is situated on the anterolateral aspect of the body of the mandible. It

is usually located below the interval between the premolars, midway between the inferior and the alveolar margins of the body, and approximately 13–15 mm superior to the inferior border of the mandibular body.^[3,6,7,15] Variations have been observed in its location, which can be more anterior, below the canine or posterior, and close to the second molar.^[23]

Previous studies have reported that AMF are commonly located below the first molar tooth.^[14,19] In the present study, though it is present in various locations, in 48%, it was present below the second premolar. It has been reported earlier that most of the AMF were located in the distal region of MF and very few in the mesial region. Mostly, AMF were found to be located inferior to the MF.^[24,25] Sekerci and Sisman reported that, in two cases, AMF were located posterior to MF.^[8] The location of AMF in relation to MF might influence the planning of rehabilitating treatment since its presence would interfere with the dental implant procedures.^[23] In the present study, most of the AMF were either inferolateral (25.9%) or superomedial (25.9%) to MF.

AMF are usually smaller than 1.0 mm, with different studies reporting the mean area of AMF to be 1.7 mm² and 1.5 mm².^[25] In the current study, the transverse diameter of most of AMFs (63%) were <1 mm. Two AMF were of larger diameter (3.04 mm and 6.0 mm), the relatively wide size might pose a surgical threat in this region.

In the present report, the distance between AMF and MF ranged from 0.5 to 8.40 mm with a mean of 2.96 mm. This was found to be similar to studies done by Garay and Cantin, Zmyslowska-Polakowska *et al.*, and Goregen *et al.*, who reported the mean distance between the AMF and MF as 3.3, 2.86, and 2.54 mm, respectively.^[26-28] This was in contrast to the studies of Naitoh *et al.* and Kalender *et al.*, where the mean MF-AMF distance was found to be 6.3 mm and 5.2 mm, respectively.^[25,29] The distance between AMF and MF is crucial while planning an implant placement in mandibular premolar region, to prevent injury to the neurovascular bundle exiting AMF. It has been recommended to consider a 2 mm distance between MF and the dental implant.^[7] We thus recommend careful exploration between 2 and 3 mm from MF and determination of presence or absence of an AMF during dental implantation procedures.

In the present study, morphometric analysis was done to determine the reference landmarks of AMF. To our knowledge, this is the first study analyzing these parameters. The distance of AMF from symphysis menti, lower border of mandible and posterior border of ramus of mandible have been measured, analyzed, and reported. Badshah *et al.* have reported morphometric measurements for a single case of AMF.^[30] No further studies were found that have recorded these parameters. These values have been determined for a better understanding of the position

and location of the AMF which will aid the clinicians in better management of patients requiring mandibular interventions.

Presurgical imaging of AMF is recommended to enable accurate planning, prevent iatrogenic injury, and contribute to successful treatment. Three-dimensional evaluation with computed tomography (CT) and cone beam CT could demonstrate the presence and course of AMF.^[8]

Failure to do peripheral neurectomy of accessory mental nerve in case of trigeminal neuralgia has resulted in recurrence of neuralgic pain and eventually failure of this procedure.^[11] It could also play a role in interpretation of anatomical landmarks in forensic medicine.^[7]

During various surgical procedures done on the mandible in the premolar and molar area such as genioplasty, bone harvesting from chin, root resection of mandibular premolars, mandibular rehabilitation after trauma, dental implant surgeries, and the presence of accessory mental nerve should be considered, to achieve a profound local anesthesia and to avoid neurovascular damage.^[8] Dental surgeons should bear in mind the possibility of an accessory mental nerve from AMF during apical curettage of mandibular premolars, filling procedures, fixation of bone fractures, surgical removal of roots, teeth, cysts, and tumors, and mandibular anterior segmental osteotomies.^[6,15]

Conclusion

The prevalence of AMF in South Indian population is relatively high and its size, shape, and its relation to the MF has been determined. Morphometric parameters of AMF have been determined in detail for the first time in Indian literature. The clinicians should be aware of the probability of existence of this AMF during any surgical procedures involving the mandibular premolar and molar region.

Financial support and sponsorship

This study was financially supported by Fluid Research Grant, Christian Medical College, Vellore.

Conflicts of interest

There are no conflicts of interest.

References

1. Haghanifar S, Rokouei M. Radiographic evaluation of the mental foramen in a selected Iranian population. *Indian J Dent Res* 2009;20:150-2.
2. Agthong S, Huanmanop T, Chentanez V. Anatomical variations of the supraorbital, infraorbital, and mental foramina related to gender and side. *J Oral Maxillofac Surg* 2005;63:800-4.
3. Mamatha NS, Kedarnath NS, Singh M, Patel G. Accessory mental nerve: A case report. *J Clin Diagn Res* 2013;7:2078-9.
4. Sawyer DR, Kiely ML, Pyle MA. The frequency of accessory mental foramina in four ethnic groups. *Arch Oral Biol* 1998;43:417-20.

5. Carter RB, Keen EN. The intramandibular course of the inferior alveolar nerve. *J Anat* 1971;108:433-40.
6. Udhaya K, Saraladevi KV, Sridhar J. The morphometric analysis of the mental foramen in adult dry human mandibles: A study on the South Indian population. *J Clin Diagn Res* 2013;7:1547-51.
7. Khojastepour L, Mirbeigi S, Mirhadi S, Safaee A. Location of mental foramen in a selected Iranian population: A CBCT assessment. *Iran Endod J* 2015;10:117-21.
8. Sekerci AE, Sisman Y. Bilateral accessory mental foramina and canals: Report of an extremely rare anatomical variation. *J Dent Implant* 2014;4:101-4.
9. Nortjé CJ, Farman AG, Grotepass FW. Variations in the normal anatomy of the inferior dental (mandibular) canal: A retrospective study of panoramic radiographs from 3612 routine dental patients. *Br J Oral Surg* 1977;15:55-63.
10. Deng W, Chen SL, Huang DY. Traumatic neuroma of mental nerve following chin augmentation. *Int J Oral Maxillofac Surg* 2009;38:1324-6.
11. Thakur G, Thomas S, Thayil SC, Nair PP. Accessory mental foramen: A rare anatomical finding. *BMJ Case Reports* 2011. DOI:10.1136/bcr.09.2010.3326.
12. Hanihara T, Ishida H. Frequency variations of discrete cranial traits in major human populations. IV. Vessel and nerve related variations. *J Anat* 2001;199:273-87.
13. Kieser J, Kuzmanovic D, Payne A, Dennison J, Herbison P. Patterns of emergence of the human mental nerve. *Arch Oral Biol* 2002;47:743-7.
14. Singh R, Srivastav AK. Study of position, shape, Size and incidence of mental foramen and accessory mental foramen in Indian adult human skulls. *Int J Morphol* 2010;28:1141-6.
15. Voljevic A, Talović E, Hasanović A. Morphological and morphometric analysis of the shape, position, number and size of mental foramen on human mandibles. *Acta Med Acad* 2015;44:31-8.
16. Oliveira-Santos C, Souza PH, De Azambuja Berti-Couto S, Stinkens L, Moyaert K, Van Assche N, *et al.* Characterisation of additional mental foramina through cone beam computed tomography. *J Oral Rehabil* 2011;38:595-600.
17. Katikireddy RS, Setty SN. Incidence of accessory mental foramen in South Indian adult dired mandibles. *Int J Anat Res* 2016;4:1916-8.
18. Hu KS, Yun HS, Hur MS, Kwon HJ, Abe S, Kim HJ, *et al.* Branching patterns and intraosseous course of the mental nerve. *J Oral Maxillofac Surg* 2007;65:2288-94.
19. Çağırankaya LB, Kansu H. An accessory mental foramen: A case report. *J Contemp Dent Pract* 2008;9:98-104.
20. Sahoo A, Tripathy R, Padhiary SK, Sahu S. Accessory mental foramen: A case report. *Int J Sci Res Publ* 2016;6:490-3.
21. Toh H, Kodama J, Yanagisako M, Ohmori T. Anatomical study of the accessory mental foramen and the distribution of its nerve. *Okajimas Folia Anat Jpn* 1992;69:85-8.
22. Hauser G, De Stefano GF. Epigenetic Variants of Human Skull. Stuttgart: Ed Schweizebart; 1989. p. 230-3.
23. Torres MG, Valverde Lde F, Vidal MT, Crusoé-Rebello IM. Accessory mental foramen: A rare anatomical variation detected by cone-beam computed tomography. *Imaging Sci Dent* 2015;45:61-5.
24. Katakami K, Mishima A, Shiozaki K, Shimoda S, Hamada Y, Kobayashi K, *et al.* Characteristics of accessory mental foramina observed on limited cone-beam computed tomography images. *J Endod* 2008;34:1441-5.
25. Naitoh M, Hiraiwa Y, Aimiya H, Gotoh K, Ariji E. Accessory mental foramen assessment using cone-beam computed tomography. *Oral Surg Oral Med Oral Pathol Oral Radiol Endod* 2009;107:289-94.
26. Garay I, Cantin M. Accessory mental foramina assessed by cone-beam computed tomography: Report of unilateral and bilateral detection. *Int J Morphol* 2013;31:1104-8.
27. Zmysłowska-Polakowska E, Radwański M, Łęski M, Ledzion S, Łukomska-Szymańska M, Polgaj M, *et al.* The assessment of accessory mental foramen in a selected Polish population: A CBCT study. *BMC Med Imaging* 2017;17:17.
28. Goregen M, Miloglu O, Ersoy I, Bayrakdar IS, Akgul HM. The assessment of accessory mental foramina using cone-beam computed tomography. *Turk J Med Sci* 2013;43:479-83.
29. Kalender A, Orhan K, Aksoy U. Evaluation of the mental foramen and accessory mental foramen in Turkish patients using cone-beam computed tomography images reconstructed from a volumetric rendering program. *Clin Anat* 2012;25:584-92.
30. Badshah M, Soames R, Khan MJ, Hasnain J, Khan J. Mental foramen (MF) morphometry in a population from Khyber Pakhtunkhwa (KP) Pakistan. *Int J Morphol* 2016;34:1228-31.