

Case Report

Minimally Invasive Correction of Prolapsed, Gangrenous Distal Limb of Loop Ileostomy to End-Loop Stoma

John Shelton  and Sittampalam Rajendra 

University Surgical Unit, Teaching Hospital, Jaffna, Sri Lanka

Correspondence should be addressed to John Shelton; jpshelton@gmail.com

Received 28 June 2020; Revised 16 October 2020; Accepted 26 October 2020; Published 6 November 2020

Academic Editor: Boris Kirshtein

Copyright © 2020 John Shelton and Sittampalam Rajendra. This is an open access article distributed under the Creative Commons Attribution License, which permits unrestricted use, distribution, and reproduction in any medium, provided the original work is properly cited.

Introduction. Prolapse can be a complication of loop stomas. A prolapsed stoma which cannot be reduced or complicated with strangulation needs surgical correction. This case report describes a minimal access correction of a prolapsed gangrenous distal limb of ileostomy. *Presentation of Case.* A 67-year-old male patient was diagnosed with a lower rectal carcinoma, staged T3N1M0. Following neoadjuvant chemoradiation, he underwent a laparoscopic anterior resection with a defunctioning loop ileostomy. One month later, he presented with prolapse of the distal limb of the ileostomy. The limb was gangrenous and the gangrenous part was removed by using a linear GI stapler, and the loop ileostomy was converted to end-loop ileostomy. *Discussion.* It is a simple and technically feasible method for treating a prolapsed loop of the stoma. It is less invasive and has minimal postoperative complications. This technique reduces the duration of the hospital stay of the patient. *Conclusion.* Stapled assisted correction of prolapsed stoma avoids unnecessary laparotomy and aids in expedite recovery after surgery. It is beneficial for a surgeon to be familiar with the minimal access correction for stoma prolapse.

1. Introduction

Diversion of faeces from the anastomotic site is achieved by creating a stoma proximally. Prolapse can be a complication of loop stomas. Prolapse occurs more frequently with loop stomas than end stomas and most frequently involves the distal limb. Patient-related risk factors for stoma prolapse include advanced age, obesity, increased intra-abdominal pressure, COPD, bowel redundancy, and weak fascia. Technical factors leading to prolapsed stoma are improper stoma site outside the rectus muscle, oversized aperture, and redundancy of the distal bowel at the stoma site [1–6].

Techniques that can limit stoma prolapse include extraperitoneal tunneling, mesentery-abdominal wall fixation, and limiting the size of the aperture. Symptoms associated with stoma prolapse include pain, skin irritation, and difficulty with maintaining an appliance and can

rarely lead to obstruction, incarceration, or strangulation. Acute stoma prolapse can often be reduced at the bedside with the aid of sugar and ice to reduce bowel wall edema, allowing for an elective repair if prolapse was to recur. Surgical options for stoma prolapse include reversal of a temporary stoma (when possible and feasible), resection, revision, or relocation [7].

A prolapsing loop stoma can be remedied by converting it into an end-loop configuration. Loop stoma conversion to an end loop stoma is performed by incising the mucocutaneous junction and transecting the bowel used to create the loop stoma into a distal and proximal segment. The prolapsed bowel segment, which tends to be the distal (efferent) limb, is closed [8–11]. Local dissection with linear cutting stapler can provide a unique and effective technique in addressing this issue when the stoma cannot be reversed. The first of this case was reported from Italy in 2003; the

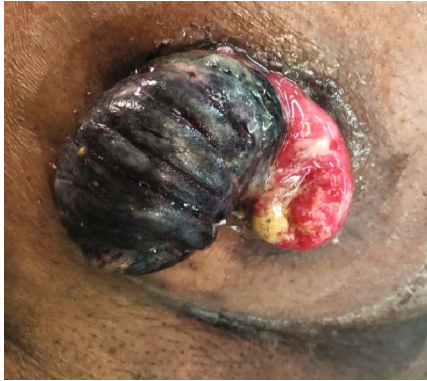

FIGURE 1: Photograph of distal loop prolapse of defunctioning loop ileostomy.

patient did not develop any postoperative recurrence or complications [12].

In this case report, we have proposed a minimally invasive correction of the prolapsed stoma to end-loop stoma by using a single liner cutting stapler, which is cost-effective and less morbidity to patients.

2. Presentation of Case

2.1. Patient Presentation. A 67-year-old Sri Lankan male patient, presented with altered bowel habit and bleeding per rectum for 18 months. A digital rectal examination revealed a rectal tumour. On colonoscopy, he was found to have a rectal mass of about 10 cm from the anal verge obstructing the lumen. The histopathology report of the biopsy from the lesion confirmed a moderately differentiated adenocarcinoma. A contrast-enhanced CT scan of the abdomen and pelvis staged the tumor as T3N1Mx.

The patient underwent neoadjuvant chemoradiotherapy and was found on restaging to have T2N0Mx tumor. He underwent standard laparoscopic low anterior resection with loop ileostomy.

After 40 days of primary surgery, he presented with a prolapsed incarcerated distal loop of ileostomy. On examination, the prolapsed distal limb of loop ileostomy was gangrenous (Figure 1). The local revision of the prolapsed segment was planned, and informed written consent was obtained for local revision with possible conversion to laparotomy.

2.2. Intervention. The surgery was performed under general anesthesia and in the supine position. After the administration of preoperative antibiotics, the gangrenous prolapsed segment was examined and confirmed to be the distal limb of the ileostomy. As the prolapsed segment was gangrenous, no reduction under general anesthesia was attempted. The prolapsed distal loop was lifted up by using two Babcock forceps. A circumferential incision was made along the mucocutaneous junction of the gangrenous bowel loop using diathermy. Dissection was carried out to liberate the prolapsed distal loop from the anterior rectus sheath and peritoneal adhesions. The

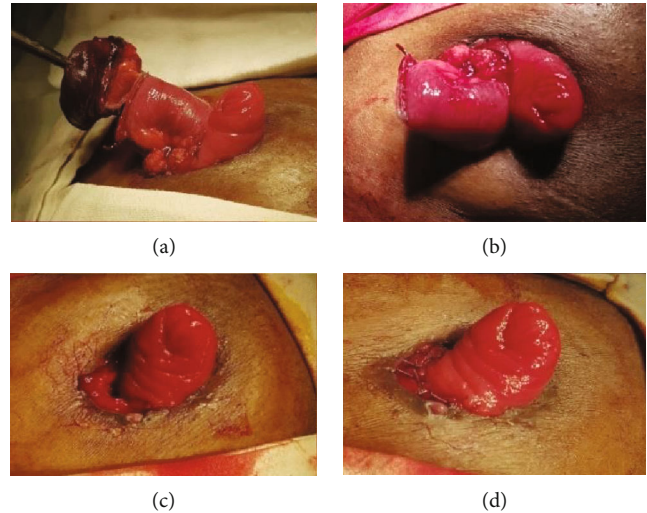


FIGURE 2: (a), (b) Prolapse distal limb stapled. (c) Distal limb reduced into the abdomen. (d) Corrected stoma prolapse.

bowel used to create the loop stoma was separated into a distal and proximal segment by transecting the wall. Some more distal loop was delivered out, and a single fire of 80 mm (COVIDIEN 80 mm-4.8 mm—UK) linear stapler device was used to close the distal limb at about 1–2 cm distal to the gangrenous part (Figures 2(a) and 2(b)). The distal loop was kept inside the peritoneal cavity. The dissected part of the proximal bowel loop was anchored to the skin using a 2/0 polyglactin suture (Figures 2(c) and 2(d)).

The final appearance of ileostomy site after complete removal of the prolapsed segment and reconstruction is that of a loop ileostomy being converted to end-loop ileostomy [13]. There was minimal blood loss, and the surgery took only 25 minutes. The proximal end of the loop ileostomy was patent and functioning. After fixing the stoma appliances, the patient was recovered from anesthesia and was transferred to the ward. He had an uneventful postoperative recovery. In the postoperative period, no opioid analgesics were used as the patient had minimal pain, and oral intake was resumed on the day of surgery. Stoma function was not affected, and he was discharged home on postoperative day one.

In the weekly postoperative follow-up, he had no evidence for recurrent prolapse, obstruction, or other complications until the ileostomy reversal. After 18 weeks of primary surgery, he underwent for routine ileostomy reversal without any difficulty.

3. Discussion

A simple and technically easy method of correction of distal loop ileostomy prolapse is described in this case report. This minimally invasive procedure consumes the most commonly available instruments including linear stapler. The functional and structural outcome of the revised stoma is good. The intraoperative bleeding was minimal, and the surgery time was short. The patient had very mild

postoperative pain, and the postoperative recovery was quick.

There are many surgical techniques described in the literature for uncomplicated stoma prolapse correction [7–11]. These techniques can be done by performing laparotomy and entry into the peritoneal cavity or local correction under local anesthesia. As this patient has presented with the gangrenous prolapsed segment, we preferred the surgery under general anesthesia with the anticipated conversion to laparotomy. The abdominal approach can result in morbidities. The local approach to revise the stoma prolapse intends to avoid these morbidities.

There are reported cases with minimally invasive stoma revision with a patent distal loop by using stapler devices [8]. In this patient, we preferred to do this distal loop closing method as the patient had just completed a month after the lower anterior resection and has to wait for another two months for ileostomy reversal.

4. Conclusion

Patients with stoma can develop complications like prolapse. Surgeons should be familiar with the minimally invasive revision for stoma prolapses. This stapler-assisted technique for stoma prolapse not only avoids unnecessary laparotomy and morbidity related to it but it also consumes less time and results in expedite recovery of the patient after surgery.

Ethical Approval

All procedures followed were in accordance with the ethical standards of the institution.

Conflicts of Interest

The authors declare that they have no conflicts of interest.

Authors' Contributions

All authors contributed equally to the study design, data collection, analysis, interpretation, writing, and drafting of this manuscript.

References

- [1] D. M. Krishnamurty, J. Blatnik, and M. Mutch, "Stoma complications," *Clinics in colon and rectal surgery*, vol. 30, no. 3, pp. 193–200, 2017.
- [2] J. Pine, L. Stevenson, and J. On, "Intestinal stomas," *Surgery*, 2019.
- [3] R. N. Saunders and D. Hemingway, "Intestinal stomas," *Surgery (Oxford)*, vol. 26, no. 8, pp. 347–351, 2008.
- [4] J. J. Park, A. Del Pino, C. P. Orsay et al., "Stoma complications," *Diseases of the colon & rectum*, vol. 42, no. 12, pp. 1575–1580, 1999.
- [5] H. Z. Geng, D. Nasier, B. Liu, H. Gao, and Y. K. Xu, "Meta-analysis of elective surgical complications related to defunctioning loop ileostomy compared with loop colostomy after low anterior resection for rectal carcinoma," *The Annals of The Royal College of Surgeons of England*, vol. 97, no. 7, pp. 494–501, 2015.
- [6] J. T. Kim and R. R. Kumar, "Reoperation for stoma-related complications," *Clinics in colon and rectal surgery*, vol. 19, no. 4, pp. 207–212, 2006.
- [7] A. C. Bafford and J. L. Irani, "Management and complications of stomas," *Surgical Clinics*, vol. 93, no. 1, pp. 145–166, 2013.
- [8] K. Masumori, K. Maeda, Y. Koide et al., "Simple excision and closure of a distal limb of loop colostomy prolapse by stapler device," *Techniques in coloproctology*, vol. 16, no. 2, pp. 143–145, 2012.
- [9] M. M. Monette, R. T. Harney, M. S. Morris, and D. I. Chu, "Local repair of stoma prolapse: case report of an in vivo application of linear stapler devices," *Annals of medicine and surgery*, vol. 11, pp. 32–35, 2016.
- [10] K. Maeda, M. Maruta, T. Utsumi et al., "Local correction of a transverse loop colostomy prolapse by means of a stapler device," *Techniques in coloproctology*, vol. 8, no. 1, pp. 45–46, 2004.
- [11] K. Tepetes, M. Spyridakis, and C. Hatzitheofilou, "Local treatment of a loop colostomy prolapse with a linear stapler," *Techniques in coloproctology*, vol. 9, no. 2, pp. 156–158, 2005.
- [12] G. Trentin, P. Simone De, P. Mainente, F. Agresta, and N. Bedin, "Repair of mucosa stomal prolapse with circular stapler. Technical note," *Chirurgia italiana*, vol. 55, no. 1, pp. 141–143, 2003.
- [13] M. L. Prasad, R. K. Pearl, C. P. Orsay, and H. Abcarian, "End-loop ileocolostomy for massive trauma to the right side of the colon," *Archives of Surgery*, vol. 119, no. 8, pp. 975–976, 1984.