



UNIVERSITY OF JAFFNA, SRI LANKA
FIRST EXAMINATION FOR MEDICAL DEGREES - JUNE 2023
ACADEMIC YEAR 2021/2022
ANATOMY PAPER II



Date: 12.06.2023

Duration: 3 Hours

Answer All TEN Questions

Answer EACH QUESTION in a separate answer book

- 1 A 70-year-old man presented with abdominal distention and bowel not opened for three days. After the investigation, he was found to have sigmoid volvulus
 - 1.1 Describe the gross anatomy of the sigmoid colon (40 Marks)
 - 1.2 How sigmoid colon can be anatomically differentiated from rectum (10 Marks)
 - 1.3 Briefly mention its relationship of sigmoid colon to adjacent structures (15 Marks)
 - 1.4 List the functions of the sigmoid colon (10 Marks)
 - 1.5 Outline the anatomical basis of developing sigmoid volvulus (15 Marks)
 - 1.6 Indicate any other clinical importance of the sigmoid colon. (10 Marks)

- 2 A 34 year old farmer presented with right side severe loin to groin pain and blood in the urine. He was diagnosed as having 1cm right side mid ureteral calculi. Line diagram of urinary tract(Figure 1) and cross section of organ A(Figure 2) are given below.

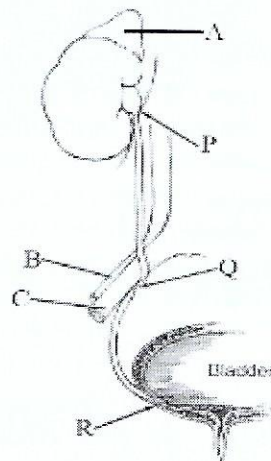


Figure 1

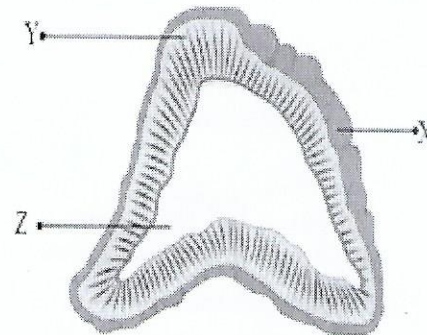


Figure 2

- 2.1 What is the length of the ureter? (10 Marks)
- 2.2 Explain the anatomical and physiological basis for loin to groin pain in ureteral obstruction? (10 Marks)
- 2.3 The three constrictions of ureter are marked as P,Q,R. Identify P,Q,R? (10 Marks)
- 2.4 Write the clinical importance of those ureteral constrictions? (10 Marks)
- 2.5 Identify the structures A,B,C? (10 Marks)
- 2.6 List the arterial supply of A and their origins? (15 Marks)
- 2.7 Outline the venous drainage of structure A in right and left sides? (10 Marks)

- 2.8 Identify X,Y,Z in figure 2? (10 Marks)
- 2.9 List the zones of structure Y and the substances produced by them (15 Marks)
- 3 A 34-year-old pregnant woman complains of tingling sensation of her right thumb and index fingers over two-months duration. She noticed some weakness of her right hand and she has begun to drop things. Neurological examinations suggestive of carpal tunnel syndrome.
- 3.1 Outline the anatomy of carpal tunnel (15 Marks)
- 3.2 Mention the landmarks to surface mark the carpal tunnel (10 Marks)
- 3.3 Name the structures passing through the carpal tunnel (20 Marks)
- 3.4 List the structures passing superficial to the carpal tunnel (10 Marks)
- 3.5 a. Which nerve is involved in carpal tunnel syndrome (05 Marks)
- b. Give a test to check the integrity of the motor function of the nerve mentioned above (10 Marks)
- c. Explain the anatomical basis of the above test (15 Marks)
- 3.6 Name sensory impairment will this patient have? (10 Marks)
- 3.7 Mention how this condition can surgically be relieved (05 Marks)
- 4 A 50-year male was admitted to the hospital with a stab injury in the middle of right posterior triangle of neck. The patient complained of shoulder drooping and difficulty in raising the right arm above the head.
- 4.1 Name the nerve most likely injured in this patient (10 Marks)
- 4.2 List the muscles supplied by the above nerve and their actions (20 Marks)
- 4.3 Outline the boundaries of the posterior triangle (30 Marks)
- 4.4 What are the other contents likely to be damaged by the stab injury in the posterior triangle? (20 Marks)
- 4.5 Write the course of right phrenic nerve within posterior triangle (20 Marks)
- 5 A 40-year male was brought to an emergency unit following an accident. Radiological investigation revealed fracture of 10th and 11th ribs on the left side. Severe haemorrhage due to ruptured spleen was controlled by splenectomy.
- 5.1 Illustrate the term “splenectomy”? (10 Marks)
- 5.2 Why spleen is vulnerable to injury in the fracture of left 10th and 11th ribs? (20 Marks)
- 5.3 Explain the anatomical basis of occurrence of severe haemorrhage in this patient? (15 Marks)
- 5.4 List the organ(s) / structure(s) supplied by the splenic artery (15 Marks)
- 5.5 List the tributaries of the splenic vein (20 Marks)
- 5.6 Outline the splenorenal ligament (20 Marks)

6 A 58 -year female was admitted to the hospital following a fall, she had pain in her right hip. During physical examination, it was noticed that her right lower limb was shortened and externally rotated. X ray revealed a complete fracture at the neck of the right femur

- 6.1 Write short notes on the stabilizing factors of hip joint (25 Marks)
- 6.2 Explain the blood supply of hip joint (15 Marks)
- 6.3 Enumerate the types of the fracture of the neck of the femur (15 Marks)
- 6.4 Explain, with reason, an expected complication of fracture neck of femur (15 Marks)
- 6.5 Briefly describe the movements of the hip joint (20 Marks)
- 6.6 Explain, on anatomical basis, the shortened and externally rotated limb (10 Marks)

7 A 32-year-old woman delivered a 4.3 kg baby and had severe bleeding (Postpartum haemorrhage) soon after the delivery. Vaginal examination revealed bleeding due to tear in the vagina and it was controlled after repair of the vaginal tear

- 7.1 Mention the structures can palpable during vaginal examination (10 Marks)
- 7.2 Describe the gross structure of vagina (30 Marks)
- 7.3 Mention the anatomical relations of the vagina (30 Marks)
- 7.4 Describe the blood supply and lymphatic drainage of vagina (30 Marks)

8 A 22-year-old male patient was brought to the emergency service due to the restriction in eye movements and diplopia. Physical examination revealed, **horizontal diplopia (Figure 1) and restriction in looking at the side was detected in the right eye.** Superior, inferior and medial vision was normal in both eyes. He had no loss of vision



Figure 1

- 8.1 Mention the nerve involved in the condition (10 Marks)
- 8.2 Describe the nerve mentioned in 8.1 under
 - a. Origin (10 Marks)
 - b. Course (15 Marks)
 - c. Innervation (10 Marks)



- 8.3 Describe the anatomical basis of the following
- a. Right eye completely in adduction (Deviation of right eye medially /internal strabismus) at rest (20 Marks)
 - b. Defect in abduction of right eye: (15 Marks)
- Imaging demonstrated an internal carotid artery aneurysm
- 8.4 Name a possible site where the nerve said in 8.1 and the internal carotid artery are in close proximity (10 Marks)
- 8.5 Explain how internal carotid artery aneurysm will lead to involvement of nerve said in 8.1 (10 Marks)

9 A 45-year female underwent total thyroidectomy. She developed hoarseness of voice immediately after surgery

- 9.1 Explain on anatomical basis of developing post-operative hoarseness of voice (20 Marks)
- 9.2 Enumerate the blood supply of thyroid gland (20 Marks)
- 9.3 Write briefly the microscopic anatomy of the thyroid gland (20 Marks)
- 9.4 Enumerate the hormones produced by the thyroid gland (10 Marks)
- 9.5 Briefly describe the development of thyroid gland (20 Marks)
- 9.6 List two (02) abnormalities during the development (10 Marks)

10 10.1

A 50-year male was admitted with progressive dysphagia for past nine months. Endoscopy detected a growth in the thoracic part of the oesophagus. It was confirmed as oesophageal cancer.

- 10.1.1 Write the function of oesophagus (10 Marks)
 - 10.1.2 Explain the development of dysphagia in oesophageal cancer (15 Marks)
 - 10.1.3 Outline the sites where constrictions are present in the oesophagus in a healthy person (15 Marks)
 - 10.1.4 Outline the arterial supply of different parts of the oesophagus (15 Marks)
 - 10.1.5 Outline the anatomical structures related to the thoracic oesophagus (25 Marks)
- 10.2 List five (05) features of autosomal recessive pattern of inheritance (20 Marks)
