

## ***Case Report***

# **Late presentation of Mullerian agenesis as primary subfertility**

**Raguraman S<sup>1</sup>, Dilinika MMS<sup>2</sup>**

<sup>1</sup>*Faculty of Medicine, Jaffna, 2 DGH Mullaitivu*

### **Abstract**

Mullerian agenesis with primary amenorrhea is a rare condition and uncommonly presented as primary subfertility. It is a complex defect in the female genital tract's embryological development.

We present a case report of a 34-year-old woman presented initially for primary subfertility management, and a systematic clinical approach such as history, examination and investigations (diagnostic laparoscopy) diagnosed Mullerian agenesis with normal development of other systems. After diagnosis, psychological counselling, vaginal dilators to improve her vaginal length and adoption were done with the multidisciplinary team approach. Community-based case study assessment and early detection of primary amenorrhea with available facilities in a low resource setting are essential elements for an early diagnosis and subsequent optimal outcomes.

### **Keywords**

Primary subfertility, Primary amenorrhea, Mullerian agenesis, Diagnostic laparoscopy

### **Introduction**

Amenorrhea defined as the absence of menses. It could further be classified into primary amenorrhea and secondary amenorrhea. In primary amenorrhea, menstruation has not occurred by the age of 14 in the absence of secondary sexual characteris-

tic or 16 even if secondary sexual characteristics are present. It is caused by several causes such as hypothalamic and pituitary disease, ovarian failure, genetic disease and female reproductive tract disorders such as Mullerian agenesis. [1]

Mullerian agenesis is a complex malformation of female genital tract development. It is characterized by congenital absence of the upper two-thirds of the vagina and an absent or rudimentary uterus in women who have normal development of secondary sexual characteristics and a 46, XX karyotype. [2] Meantime, it may associate with other systems abnormalities such as renal and cardiac. The disorder is relatively common in women presenting with primary amenorrhea. [3]

Here we present a case of primary amenorrhea, which presented with coital dysfunction and primary subfertility and further investigated and diagnosed as Mullerian agenesis.

### **Case presentation**

Thirty-four-year-old women with hypertension and dyslipidemia referred by a medical clinic for further management of primary subfertility. She was married for two years. The onset of thelarche and pubarche were age-appropriate but did not report menstrual bleeding nor cyclical pelvic pain and never sought medical help. She complained of pain and difficulties in her sexual life.

**Corresponding author:** Raguraman S, email-sivalingarajahraguraman@gmail.com, <https://orcid.org/0000-0002-7822-0447>,  
Submitted June 2021 Accepted December 2021



This is an open-access article distributed under the terms of the Creative Commons Attribution 4.0 International License, which permits unrestricted use, distribution and reproduction in any medium provided the original author and source are credited

She was extensively investigated for young hypertension, and all investigations were normal. She was on losartan 50mg twice per day and amlodipine 5mg twice per day with satisfactory blood pressure control. Her dyslipidemia satisfactorily controlled with diet modification. She does not have a significant surgical, family and allergy history. Her mother had no exposure to radiation or hormonal drugs while she was in-utero and delivered at term by uncomplicated vaginal delivery.

On examination, she had normal height weight, BMI and arm span. Her breasts development and pubic hair distribution were normal (Tanner stage 5). Her External genitalia was normal, and digital vaginal examination revealed a blind end vagina with a length of 1.5cm without a cervix. All other systemic examinations were normal.

Her basic blood investigations were normal, and an ultrasound scan of the pelvis visualized both ovaries but not able to visualize the uterus. An ultrasound scan of the abdomen was normal Her hormone profile of FSH, LH, prolactin, testosterone and thyroxine levels were normal, and her karyotype was 46XX. Diagnostic laparoscopy of pelvic cavity should the absence of uterus with normal bilateral ovaries and tubes.

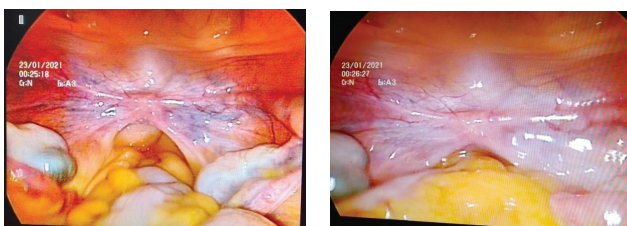


Fig 1. Laparoscopic view of pelvis show absence of uterus with normal bilateral ovaries

Following the assessment, we counselled and explained to the couple about her diagnosis (Mullerian agenesis), sexual functions and fertility options. The diagnosis was explained with a consultant gynaecologist lead team with a professional counsellor. To improve her sexual function, we arranged

and demonstrated three different vaginal dilators and planned to review her every six months to assess the improvement. Vaginoplasty will be considered if she is not improving her vaginal length by one year. In terms of fertility management, surrogacy and assisted reproductive technology with their gamete options were discussed since she had a good ovarian reserve (Anti Mullerian hormone level was 3.1) and her husband's SFA was normal. However, the couple had financial constraints and opted for adoption.

## Discussion

Müllerian agenesis also referred to and described in different terminologies in literature such as Mullerian aplasia, Mayer–Rokitansky–Küster–Hauser syndrome and vaginal agenesis. [4] Incidence of Mullerian agenesis is reported in several case series as 1 per 4,500–5,000 females. [4] Müllerian agenesis is caused by embryologic underdevelopment of the Mullerian duct, with resultant agenesis or atresia of the vagina, uterus, or both. The vaginal canal is markedly shortened and may appear as a dimple below the urethra. The ovaries, given their separate embryologic source, are typically normal in structure and function, though they may be found in atypical locations. However, it may associate with other systems abnormalities such as renal, cardiac and skeletal system.

The differential diagnosis of a patient presenting with primary amenorrhea and a shortened lower vagina includes structural abnormality of vaginal or uterus such as imperforate hymen, transverse vaginal septum, distal vaginal atresia and cervical atresia, Mullerian agenesis and 46, XY disorders of sex development such as androgen insensitivity syndrome. The evaluation should comprise clinical assessment and evaluation of female reproductive tract, hormonal profile and karyotype assessment.

Around 53% of patients with müllerian agenesis have concomitant other system congenital malformations. [5] Magnetic resonance imaging (MRI) is more sensitive and specific to diagnose Mullerian agenesis than ultrasonography. [6] MRI has replaced laparoscopy for complete anatomical evaluation and is considered the gold standard. However, laparoscopy still plays an essential role in diagnosing pelvic structure. [7, 8]

Müllerian agenesis is one of the most common causes of primary amenorrhea. On the other hand, androgen insensitivity syndrome often presents with primary amenorrhea, shortened vagina, and absent cervix. They will produce normal androgens, but peripheral aromatization would not occur due to androgen receptors are insensitive to androgen. Therefore, they have typical breast development because of the peripheral aromatization of testosterone to estrogen, and lack of functional androgen receptors results in decreased or absent pubic and axillary hair.

Management includes psychological counselling, sexual life improvement and fertility. All patients with müllerian agenesis should be offered psychological counselling and encouraged to connect with peer support groups. Primary vaginal elongation by vaginal dilators is an appropriate first-line approach in most patients because it is safer, patient-controlled, and more cost-effective than surgery. [9] A 90-96% of well-counselled and emotionally prepared patients will be able to achieve anatomic and functional success by primary vaginal dilation. [10] Surgical creation of neovagina is undertaken if non-surgical methods fail or if the woman chooses a surgical option at the outset. In terms of fertility management, assisted reproductive techniques with the couple's gametes using a gestational carrier (surrogate) be successful for women with müllerian agenesis.

## Conclusion

Mullerian agenesis with primary amenorrhea and subfertility is a rare presentation and challenge to manage by a gynaecologist and fertility specialist. Diagnostic laparoscopy will play a pivotal role to diagnosed Mullerian agenesis in a low resource setting. However, early presentation and detection by clinicians will effectively treat the patient with multidisciplinary approaches in terms of sexual health and fertility outcomes. Community-based case studies of primary amenorrhea will aid in the early detection and management of Mullerian agenesis with optimal outcomes.

## Reference

1. Lesley M, Kilby D, Obstetrics & Gynaecology an evidence-based text for the MRCOG. UK, third edition, CRC Press; 2016.
2. Valappil S, Chetan U, Wood N, Garden A. Mayer-Rokitansky-Kuster-Hauser syndrome: diagnosis and management. "The Obstetrician & Gynaecologist 2012; 14:93-98
3. Morcel K, Camborieux L, Guerrier D. Programme de Recherches sur les Aplasies Mulleriennes, Mayer-Rokitansky-Kuster-Hauser (MRKH) " syndrome. Orphanet J Rare Dis 2007; 2:13 [http://dx.doi.org/10.1186/1750-1172-2-13]
4. Fontana L, Gentilin B, Fedele L, Gervasini C, Miozzo M. Genetics of Mayer-Rokitansky-Kuster-Hauser (MRKH) syndrome. Clin Genet 2017; 91:233-46.
5. Oppelt P, Renner SP, Kellermann A, Brucker S, Hauser GA, Ludwig KS, et al. Clinical aspects of Mayer-Rokitansky-Kuester-Hauser syndrome: recommendations for clinical diagnosis and staging. Hum Reprod 2006; 21:792-7.

6. Govindarajan M, Rajan RS, Kalyanpur A, Ravikumar. Magnetic resonance imaging diagnosis of Mayer–Rokitansky–Kuster–Hauser “ syndrome. *J Hum Reprod Sci* 2008; 1:83–5 [http://dx.doi.org/10.4103/0974-1208.44117]
7. Preibsch H, Rall K, Wietek BM, Brucker SY, Staebler A, Claussen CD, et al. Clinical value of magnetic resonance imaging in patients with Mayer-Rokitansky-Kuster-Hauser (MRKH) syndrome: diagnosis of associated malformations, uterine rudiments and intrauterine endometrium. *Eur Radiol* 2014; 24:1621–7.
8. Laufer MR. Structural abnormalities of the female reproductive tract. In: Emans SJ, Laufer MR, editors. *Pediatric and adolescent gynaecology*. 6th ed. Philadelphia (PA): Wolters Kluwer; Lippincott Williams & Wilkins; 2012. p. 177–237.
9. Willemsen WN, Kluivers KB. Long-term results of vaginal construction with the use of Frank dilation and a peritoneal graft (Davydov procedure) in patients with Mayer-Rokitansky-Kuster syndrome. *Fertil Steril* 2015; 103:220–7.
10. Gargollo PC, Cannon GM Jr, Diamond DA, Thomas P, Burke V, Laufer MR. Should progressive perineal dilation be considered first-line therapy for vaginal agenesis? *J Urol* 2009; 182:1882–9.