



UNIVERSITY OF JAFFNA, SRI LANKA  
FINAL EXAMINATION FOR MEDICAL DEGREES FEBRUARY 2023  
ACADEMIC YEAR 2015/2016  
SURGERY – PAPER II

Date: 23.02.2023

Duration: 01.30 Pm - 04.30 Pm (3 Hours)

Answer All Eight (8) Questions

INDEX NO. : .....

Question Number: 01

A 60-year old man who underwent an open splenectomy through a subcostal incision has just arrived in the surgery ward from the operating theatre.

1.1. How you will immediately assess the patient? (30 marks)

-----  
-----  
-----  
-----  
-----  
-----  
-----  
-----  
-----

1.2. What are the subjective and objective ways in which pain can be clinically assessed in this patient? (20 marks)

-----  
-----  
-----  
-----  
-----



UNIVERSITY OF JAFFNA, SRI LANKA

FINAL EXAMINATION FOR MEDICAL DEGREES -FEBRUARY 2023

ACADEMIC YEAR 2015/2016

SURGERY – PAPER II

Date: 23.02.2023

Duration: 01.30 Pm - 04.30 Pm (3 Hours)

Answer All Eight (8) Questions

INDEX NO. : .....

1.3. Write a prescription for pain relief for this patient for the first 24-hour period after surgery. His weight was recorded as 75 kg, and he is known to be allergic to NSAIDs. (10 marks)

-----  
-----  
-----  
-----

1.4. Discuss the physical and psychological effects this patient may suffer from pain. (40 marks)

-----  
-----  
-----  
-----  
-----  
-----  
-----  
-----  
-----  
-----  
-----  
-----  
-----  
-----  
-----  
-----  
-----  
-----



**UNIVERSITY OF JAFFNA, SRI LANKA**  
**FINAL EXAMINATION FOR MEDICAL DEGREES -FEBRUARY 2023**  
**ACADEMIC YEAR 2015/2016**  
**SURGERY – PAPER II**

**Date: 23.02.2023**

**Duration: 01.30 Pm - 04.30 Pm (3 Hours)**

**Answer All Eight (8) Questions**

**INDEX NO. : .....**

**Question Number: 02**

A 40-year old man was admitted to the emergency department following a road traffic crash a few hours ago. The primary survey revealed that he is haemodynamically stable and has no life-threatening injuries. But he has a swollen right leg and a bleeding laceration over the anterior aspect of the tibia. An open fracture of the right tibia is suspected.

2.1. Explain the term “open fracture”? (20 marks)

-----  
 -----  
 -----  
 -----

2.2. Briefly outline the initial assessment of this patient. (25 marks)


-----  
 -----  
 -----  
 -----  
 -----

2.3. What investigation you will order to confirm the diagnosis? (10marks)

-----



UNIVERSITY OF JAFFNA, SRI LANKA  
FINAL EXAMINATION FOR MEDICAL DEGREES - FEBRUARY 2023  
ACADEMIC YEAR 2015/2016  
SURGERY – PAPER II



Date: 23.02.2023

Duration: 01.30 Pm - 04.30 Pm (3 Hours)

Answer All Eight (8) Questions

INDEX NO. : .....

2.4. Describe the initial management of this patient. (30 marks)

.....

.....

.....

.....

.....

.....

.....

.....

.....

.....

.....

.....

.....

.....

.....

.....

.....

.....

.....

.....

.....

.....

2.5. Mention three (3) expected early complications of this open fracture. (15 marks)

.....

.....

.....



UNIVERSITY OF JAFFNA, SRI LANKA  
FINAL EXAMINATION FOR MEDICAL DEGREES -FEBRUARY 2023

ACADEMIC YEAR 2015/2016

SURGERY – PAPER II

Date: 23.02.2023

Duration: 01.30 Pm - 04.30 Pm (3 Hours)

Answer All Eight (8) Questions

INDEX NO. : .....

Question Number: 03

3.1. A 30-year old woman presented with a 2 cm X 2 cm dominant nodule in the right lobe of the thyroid for six months.

a. Mention three (3) investigations to arrive at a diagnosis with interpretations.

(10 Marks)

-----  
-----  
-----  
-----  
-----  
-----  
-----  
-----

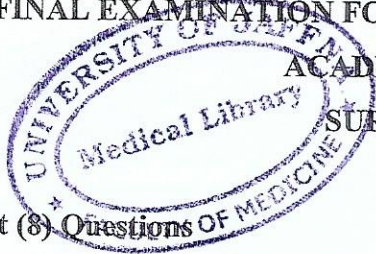
b. Enumerate the management of one of the malignant lesions in the above patient.

(25 Marks)

-----  
-----  
-----  
-----  
-----  
-----  
-----



UNIVERSITY OF JAFFNA, SRI LANKA  
 FINAL EXAMINATION FOR MEDICAL DEGREES -FEBRUARY 2023  
 ACADEMIC YEAR 2015/2016



Date: 23.02.2023

Duration: 01.30 Pm - 04.30 Pm (3 Hours)

Answer All Eight (8) Questions

SURGERY – PAPER II

INDEX NO. : .....

-----  
 -----

- 3.2. A 40-year old woman diagnosed with parathyroid adenoma was admitted to the surgical ward.
- a. Mention five investigations with interpretations to arrive at the above diagnosis in this patient. (20 Marks)

-----  
 -----  
 -----  
 -----  
 -----  
 -----  
 -----  
 -----

- b. Mention two methods to identify the parathyroid adenoma during surgery. (10 Marks)

-----  
 -----



**UNIVERSITY OF JAFFNA, SRI LANKA**  
**FINAL EXAMINATION FOR MEDICAL DEGREES -FEBRUARY 2023**  
**ACADEMIC YEAR 2015/2016**  
**SURGERY – PAPER II**

**Date: 23.02.2023**

**Duration: 01.30 Pm - 04.30 Pm (3 Hours)**

**Answer All Eight (8) Questions**

**INDEX NO. : .....**

3.3. A 50-year old woman presented with blood stained discharge through the nipple of the right breast.

a. List three causes for the nipple discharge in the above woman. (15 Marks)

-----  
 -----  
 -----

b. How will you differentiate above mentioned causes from the history? (20 Marks)

-----  
 -----  
 -----  
 -----  
 -----



UNIVERSITY OF JAFFNA, SRI LANKA  
**FINAL EXAMINATION FOR MEDICAL DEGREES - FEBRUARY 2023**  
 ACADEMIC YEAR 2015/2016  
**SURGERY – PAPER II**

Date: 23.02.2023

Duration: 01.30 Pm - 04.30 Pm (3 Hours)

Answer All Eight (8) Questions

INDEX NO. : .....

**Question Number: 04**

A previously healthy 5-week-old baby boy born at 39 weeks of gestation following an uncomplicated pregnancy, is brought to the accident & emergency with a 3-day history of forceful vomiting after feeding, which is nonbilious. In addition, a distinct 1 cm, olive-like mass is felt on physical examination in the upper abdomen.

4.1. What is the most likely clinical diagnosis? (10 marks)

-----

4.2. What other signs would you see in your clinical examination of this baby? (30 marks)

-----  
 -----  
 -----  
 -----  
 -----

4.3. Mention the investigation which confirms your clinical diagnosis. (05 marks)

-----






**UNIVERSITY OF JAFFNA, SRI LANKA**  
**FINAL EXAMINATION FOR MEDICAL DEGREES -FEBRUARY 2023**  
**ACADEMIC YEAR 2015/2016**  
**SURGERY – PAPER II**

Date: 23.02.2023

Duration: 01.30 Pm - 04.30 Pm (3 Hours)

Answer All Eight (8) Questions



INDEX NO. : .....

4.4. What is the acid-base and electrolyte imbalance you would expect in this baby on admission? (20 marks)

-----  
 -----  
 -----

4.5. Mention the important steps in the initial management of this baby. (15 marks)

-----  
 -----  
 -----  
 -----

4.6. What is the definitive management of the above mentioned condition in 4.1? (05 Marks)

-----

Mother of the baby is concerned about feeding the baby after the surgery.

4.7. What advice would you give her about feeding the baby after surgery? (15 Marks)

-----  
 -----  
 -----



UNIVERSITY OF JAFFNA, SRI LANKA  
 FINAL EXAMINATION FOR MEDICAL DEGREES - FEBRUARY 2023  
 ACADEMIC YEAR 2015/2016  
 SURGERY – PAPER II

Date: 23.02.2023

Duration: 01.30 Pm - 04.30 Pm (3 Hours)

Answer All Eight (8) Questions

INDEX NO. : .....

**Question Number: 05**

A 59 year old man, farmer presented with painful visible haematuria, dysuria and frequency.

5.1. List 3 differential diagnoses. (10 Marks)

-----  
 -----  
 -----

5.2. Briefly write on further information you would obtained from the history to arrive at a diagnosis. (20 Marks)

-----  
 -----  
 -----  
 -----  
 -----  
 -----  
 -----

5.3. How will you investigate this patient? (20 Marks)

-----  
 -----  
 -----



UNIVERSITY OF JAFFNA, SRI LANKA  
 FINAL EXAMINATION FOR MEDICAL DEGREES -FEBRUARY 2023  
 ACADEMIC YEAR 2015/2016  
 \*SURGERY – PAPER II

Date: 23.02.2023

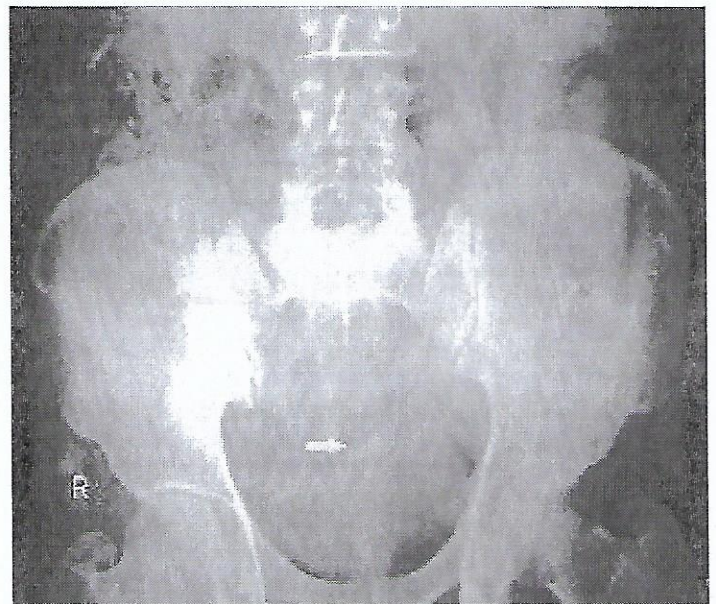
Duration: 01.30 Pm - 04.30 Pm (3 Hours)

Answer All Eight (8) Questions

INDEX NO. : .....

-----  
 -----  
 -----

His X-ray/KUB is given here.



(10 Marks)

5.4. Describe the finding in this X-ray/KUB, and what is the most likely diagnosis?

-----  
 -----

5.5. List 3 other differential diagnoses for the above shadow in X-ray KUB? (10 Marks)

-----  
 -----  
 -----



**UNIVERSITY OF JAFFNA, SRI LANKA**  
**FINAL EXAMINATION FOR MEDICAL DEGREES -FEBRUARY 2023**  
**ACADEMIC YEAR 2015/2016**

**SURGERY – PAPER II**

**Date: 23.02.2023**

**Duration: 01.30 Pm - 04.30 Pm (3 Hours)**

**Answer All Eight (8) Questions**

**INDEX NO. : .....**

5.6. What is the investigation that will confirm your diagnosis? (10 Marks)

-----

5.7. How will you manage if he presents with acute urine retention? (10 Marks)

-----

5.8. What is the definitive management of this patient's condition? (10 Marks)

-----  
 -----



**UNIVERSITY OF JAFFNA, SRI LANKA**  
**FINAL EXAMINATION FOR MEDICAL DEGREES -FEBRUARY 2023**  
**ACADEMIC YEAR 2015/2016**  
**SURGERY – PAPER II**

**Date: 23.02.2023**

**Duration: 01.30 Pm - 04.30 Pm (3 Hours)**

**Answer All Eight (8) Questions**

**INDEX NO. : .....**

**Question Number: 06**

A 65-year-old known patient with Atrial fibrillation(AF) who was on warfarin defaulted treatment for two weeks duration presented to A & E with the sudden onset of right leg pain for a 3-hour duration

6.1. List two (2) possible causes for the leg pain in this patient. (10 Marks)

-----  
 -----

6.2. On examination, on the right side, only femoral pulse was palpable. On the left side, all the peripheral pulses were palpable. What is the most likely diagnosis (5 Marks)

-----

6.3. How do you define the above condition? (15 Marks)

-----  
 -----  
 -----  
 -----  
 -----  
 -----



UNIVERSITY OF JAFFNA, SRI LANKA  
FINAL EXAMINATION FOR MEDICAL DEGREES -FEBRUARY 2023

ACADEMIC YEAR 2015/2016

SURGERY - PAPER II

Date: 23.02.2023

Answer All Eight (8) Questions

Duration: 01.30 Pm - 04.30 Pm (3 Hours)



INDEX NO. : .....

6.4. How do you assess the patient initially? (20 Marks)

-----  
-----  
-----  
-----  
-----  
-----  
-----  
-----  
-----  
-----

6.5. List 4 possible causes for the condition mentioned in 6.2. (10 Marks)

-----  
-----  
-----  
-----

6.6. How do you manage this patient on admission? (20 Marks)

-----  
-----



UNIVERSITY OF JAFFNA, SRI LANKA  
**FINAL EXAMINATION FOR MEDICAL DEGREES -FEBRUARY 2023**  
 ACADEMIC YEAR 2015/2016  
**SURGERY – PAPER II**

Date: 23.02.2023

Duration: 01.30 Pm - 04.30 Pm (3 Hours)

Answer All Eight (8) Questions

INDEX NO. : .....

-----  
 -----  
 -----  
 -----  
 -----  
 -----  
 -----

6.7. List two definitive management options for this patient. (10 Marks)

-----  
 -----

6.8. Mention one drug that can be used instead of warfarin and two advantages of this drug over warfarin. (10 Marks)

-----  
 -----



**UNIVERSITY OF JAFFNA, SRI LANKA**  
**FINAL EXAMINATION FOR MEDICAL DEGREES -FEBRUARY 2023**  
**ACADEMIC YEAR 2015/2016**  
**SURGERY – PAPER II**

Date: 23.02.2023

Duration: 01.30 Pm - 04.30 Pm (3 Hours)

Answer All Eight (8) Questions



INDEX NO. : .....

**Question Number: 07**

A 46-year old woman who underwent laparoscopic cholecystectomy a week ago presented with upper abdominal pain, yellow discolouration of sclera and fever for two days. Her blood pressure is 90/60 mmHg, and her pulse rate is 110 beats/minute.

7.1. What is the possible diagnosis of this patient? (15 Marks)

.....

7.2. List the steps in the initial management of this patient. (25 Marks)

.....  
 .....  
 .....  
 .....  
 .....

7.3. How would you investigate this patient? (20 Marks)

.....  
 .....  
 .....  
 .....





UNIVERSITY OF JAFFNA, SRI LANKA  
FINAL EXAMINATION FOR MEDICAL DEGREES -FEBRUARY 2023

ACADEMIC YEAR 2015/2016

SURGERY – PAPER II

Date: 23.02.2023

Duration: 01.30 Pm - 04.30 Pm (3 Hours)

Answer All Eight (8) Questions



INDEX NO. : .....

7.4. List four (4) possible causes for the above condition. (20 Marks)

-----  
-----  
-----  
-----

7.5. Mention the treatment options for the above-mentioned causes in 7.4. (20 Marks)

-----  
-----  
-----  
-----  
-----




UNIVERSITY OF JAFFNA, SRI LANKA  
 FINAL EXAMINATION FOR MEDICAL DEGREES -FEBRUARY 2023  
 ACADEMIC YEAR 2015/2016  
 SURGERY – PAPER II

Date: 23.02.2023

Duration: 01.30 Pm - 04.30 Pm (3 Hours)

Answer All Eight (8) Questions



INDEX NO. : .....

**Question Number: 08**

A ninety-year-old male patient presented with acute onset of pain in left iliac fossa for two days. He had constipation for seven days, and he also has poorly controlled diabetes, end-stage renal failure, bronchiectasis and congestive heart failure. Physical examination revealed a tender left lower abdomen. A CT scan of his abdomen revealed many sac-like protrusions in the sigmoid and descending colon. There was no free fluid in the left iliac fossa.

8.1. What is the most likely diagnosis? (5 Marks)

-----

8.2. List the biochemical investigations that you will request in this patient. (15 Marks)


-----  
 -----  
 -----  
 -----  
 -----

8.3. Describe the immediate management of this patient. (25 Marks)

-----  
 -----  
 -----  
 -----  
 -----  
 -----  
 -----



**UNIVERSITY OF JAFFNA, SRI LANKA**  
**FINAL EXAMINATION FOR MEDICAL DEGREES -FEBRUARY 2023**  
**ACADEMIC YEAR 2015/2016**



**Date: 23.02.2023**

**Answer All Eight (8) Questions**

**Duration: 01.30 Pm - 04.30 Pm (3 Hours)**

**INDEX NO. : .....**

8.4. Considering the patient's co-morbidities, what precautions you would take in the immediate management? (15 Marks)

-----  
 -----  
 -----  
 -----  
 -----

Three (3) days after the commencement of treatment, the patient developed fever spikes, tachycardia, and increasing tenderness in the left iliac fossa. A repeat CT scan evaluation of the abdomen revealed fluid collection (>3 cm) around the sigmoid colon with no gas in the peritoneal cavity.

8.5. What is the most likely cause of the clinical condition? (5 Marks)

-----

8.6. What is the suitable treatment for this patient's condition? (10 Marks)

-----

8.7. Enumerate the other complications of the condition mentioned in 8.1. (10 Marks)

-----  
 -----



UNIVERSITY OF JAFFNA, SRI LANKA  
FINAL EXAMINATION FOR MEDICAL DEGREES -FEBRUARY 2023  
ACADEMIC YEAR 2015/2016  
SURGERY – PAPER II



Date: 23.02.2023

Duration: 01.30 Pm - 04.30 Pm (3 Hours)

Answer All Eight (8) Questions

INDEX NO. : .....

8.8. If the patient recovers, what advice you will give him when discharge?

(15 Marks)

-----  
-----  
-----