

UNIVERSITY OF JAFFNA, SRI LANKA
FIRST EXAMINATION FOR MEDICAL DEGREES (1st) –AUGUST 2020
ANATOMY – PAPER II

Date : 24.08.2020

Time: Three hours

Answer all TEN questions

Answer EACH QUESTION in a separate answer book

1. A 34 year man presented with right upper leg swelling after a sports injury. The radiological investigation revealed fracture at the neck of right side fibula. On physical examination, decreased sensation in the anterior and lateral side of the leg along with an inability to dorsiflex the right foot was noted.
 - 1.1 Which structure is likely to be injured in this patient? (15 Marks)
 - 1.2 Write short notes on formation, course and branches of structure mentioned above in 1.1 (30 Marks)
 - 1.3 Enumerate the structures passes through superior extensor retinaculum in order from medial to lateral (20 Marks)
 - 1.4 Surface mark the dorsalis pedis artery (15 Marks)
 - 1.5 Outline the dermatome pattern of the foot (20 Marks)

2. A 43 year man presented with pain and swelling in the right submandibular region. The pain was aggravated after the meal. Bimanual palpation of floor of the mouth revealed a solid mass in the right side.
 - 2.1 What is the most likely diagnosis? (15 Marks)
 - 2.2 Write short notes on the anatomical course of the affected structure and it's closest related structures (35 Marks)
 - 2.3 Describe the gross anatomy of this gland (35 Marks)
 - 2.4 Name the structures at risk during the surgical operation of this gland (15 Marks)

3. A.

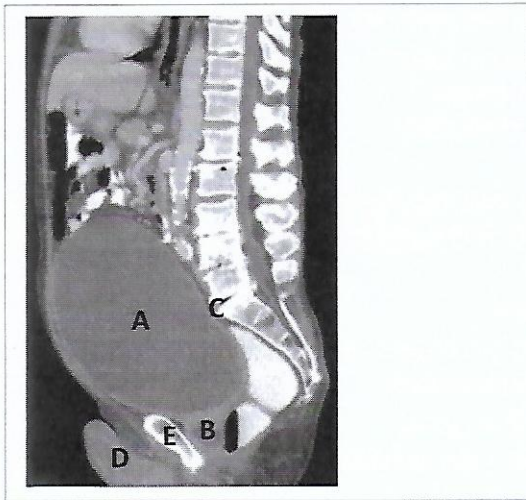
A 65 year man with a right dominance heart had a coronary bypass surgery. Sternum was split to access the internal structures / organs.

 - 3.1 Mention the artery more commonly occluded? (10 Marks)
 - 3.2 Mention the structure(s) that connects the sternum with pericardium (10 Marks)
 - 3.3 Briefly describe the term “ right dominance heart” (20 Marks)
 - 3.4 Write notes on anastomosis of coronary arteries (30 Marks)
 B.

Outline the causes of Down syndrome (30 Marks)

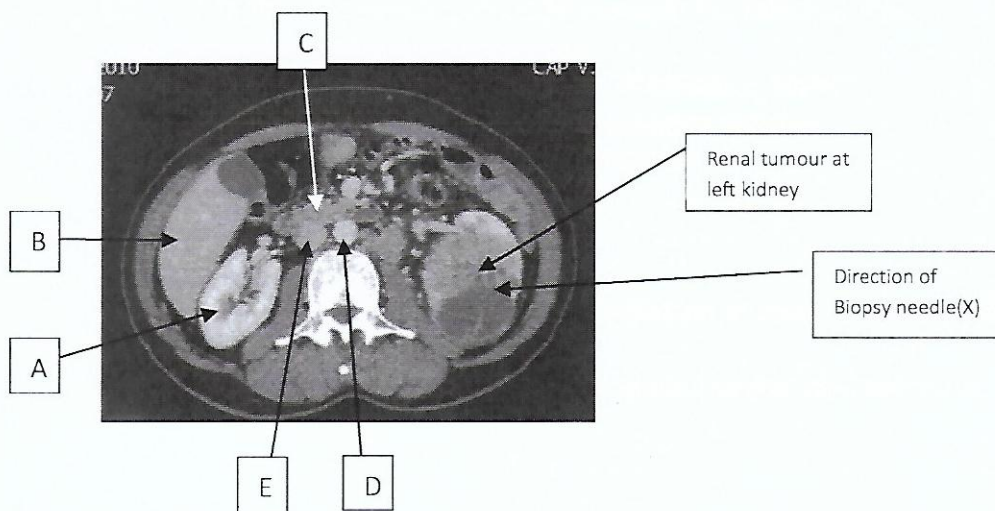
4.
 - 4.1 Outline the blood supply of colon (35 Marks)
 - 4.2 Write notes on midline surgical incision of anterior abdominal wall (35 Marks)
 - 4.3 Immediate anatomical relations of second part of duodenum (30 Marks)

5. A 42 year woman **had loss of pain and temperature sensation on the right side of her face and left side of her body**. She also had **hoarseness, difficulty in swallowing, vertigo and nystagmus**. On examination **right sided partial ptosis and meiosis** were seen. CT scan of the brain showed an infarct on the right side of the medulla oblongata
- 5.1 Write the diagnosis of the clinical condition mentioned above (10 Marks)
- 5.2 Write the important vessel which is responsible for above condition (5.1) (10 Marks)
- 5.3 Indicate the nuclei / tracts affected in the lesion (10 Marks)
- 5.4 Explain the anatomical basis of features mentioned in bold letters (40 Marks)
- 5.5 Describe the posterior circulation of brain (30 Marks)
6. A 76 year man presented with severe abdominal pain with reduced urine output. He was obese. It was difficult to feel the abdomen. He had past history of kidney stone and CT/KUB was done. CT image is given below.



- 6.1 Mention the view of this CT (05 Marks)
- 6.2 Identify the structures A, B, C, D, E (15 Marks)
- 6.3 Digital rectal examination (DRE) revealed enlarged prostate. Further investigation confirmed benign prostatic enlargement. With a labeled diagram show the zones of the prostate and the relations of the prostate gland (40 Marks)
- 6.4 Indicate in the above diagram which zone is more prone to benign prostatic enlargement (10 Marks)
- 6.5 Urethral catheter was inserted to empty the bladder. Explain the path urethral catheter will travel during insertion (15 Marks)
- 6.6 Urethral catheterisation was failed and a suprapubic catheterization (SPC) was done. Name the structures pierced during SPC insertion (15 marks)

7. Regarding the female breast
- 7.1 Write the structures forming the breast bed (20 Marks)
- 7.2 Mention the anatomical extent of the female breast (20 Marks)
- 7.3 List the arteries supply to the breast (20 Marks)
- 7.4 Write notes on the light microscopic structure of adult mammary gland (25 Marks)
- 7.5 List three anomalies during the development of breast (15 Marks)
8. A 35 year man was admitted to the hospital after heavy intake of alcohol and complaining of severe constant abdominal pain with nausea and vomiting. The pain radiates to the back of the upper abdomen. The serum amylase and lipase levels were markedly elevated.
- 8.1 Write the probable diagnosis of the above condition (10 Marks)
- 8.2 Write the blood supply of the above structure (30 Marks)
- 8.3 Describe briefly the development of the above structure and enumerate two abnormalities (35 Marks)
- 8.4 Write notes on microscopic anatomy of the above structure (25 Marks)
9. A 6 year boy fell down while playing in the mat-slide was brought to hospital with pain and swelling over left elbow. He was found to have left supracondylar fracture of humerus
- 9.1 Describe the relationship of ulna, radial and median nerves to supracondylar region of humerus (50 Marks)
- 9.2 Write two tests that you would do to assess each nerve in the hand (50 Marks)
10. A 65 year male admitted to hospital with left loin pain and blood in urine. On examination he had left side scrotal varicocele (dilated pampiniform plexus). His CT scan image is given below which revealed suspicious small renal mass (Cross section at L1 level). He underwent biopsy of left side renal tumour via left flank. Eventually left side radical Nephrectomy (complete removal of kidney and coverings) was done.



- 10.1 Identify the organs A,B,C and major vessels D,E (20 Marks)
- 10.2 List the structures (Superficial to deep) those are pierced by needle (x) during renal tumour biopsy via loin (20 Marks)
- 10.3 Explain the anatomical basis for persistent left side varicocele in left renal cancer which is not seen in right side renal cancer (25 Marks)
- 10.4 Describe the structures surgeon will encounter during left radical Nephrectomy (Relations of left kidney) (35 Marks)
